

Intraoral lipoma- A case report

Dr. Shreeja Pillai

Department of Oral Pathology, S.M.B.T Institute of Dental Science and Research, Nashik, Maharashtra, India

Abstract

Lipoma is a benign tumour that mostly affects middle-aged people and seldom affects the Oral cavity. The optimal therapeutic strategy to be considered is surgical conservative care due to its non-invasive behaviour and low recurrence rate. This report focuses on two patients and the treatments that led to better health for them.

Keywords: lipoma, benign, mesenchymal, adipocyte

Introduction

Lipomas make up between 0.1 and 5% of all benign tumours of the mouth, making them the most prevalent soft tissue neoplasm. 1–4% of instances, affect the oral cavity, which is a rare site for these cases [1, 2]. Lipomas can be undetectable lesions for years before their size interferes with normal masticatory function and produces aesthetic issues. However, because the mass is benign, it rarely causes a major risk to health. They are rather infrequent lesions, and recurrence is uncommon following removal [3]. A benign tumour of mesenchymal origin called an oral lipoma is made up of mature adipocytes and is typically enclosed in a thin capsule of fibrous connective tissue [4, 5]. Only 1%–4% of soft tissue lipomas, which account for 15%–20% of all cases, are seen intraorally in the head and neck region [5]. The maxillofacial region has a very low incidence of intraoral lipoma [IOL] about 0.1% and is rarely affected [5].

Incidence

Due to the extensive nature of the lesion, the occurrence of this tumour seems to be correlated with the amount of adipose tissue. Due to its proximity to the buccal fat pad, the buccal mucosa has a lot of adipose tissue and is where lipomas are more frequently seen [6, 7]. The metaphysis of long bones and the medullary bone of the calcaneus are frequent sites for IOL, with the jaw being regarded as an unusual site [8].

Etiology

Oral lipoma's aetiology is unknown. According to certain research, the formation of oral lipomas may be influenced by mechanical factors, the endocrine system, inflammation, obesity, chromosomal anomalies, radiation, trauma, mucosal infections, and chronic irritation [9].

Case report

A 56-year-old man visited the Department of Oral and Maxillofacial Pathology complaining of a swelling on the buccal mucosa that started one year prior. The swelling had worsened over the previous two months and he had discomfort while eating. Upon intraoral examination, we observed swelling at the right first premolar region on the buccal mucosa extending till the mandibular vestibule and palpated a relatively solid mass, measuring approximately 2.0×1.5 cm and covered with normal tissue. The patient did not complain of any pain when the mass was palpated. Aspiration analysis confirmed negative findings. We did not observe any other mass on the other sites in the intraoral cavity and cervical lymph nodes were not swollen. Fig. 1 shows extraoral photograph Fig 2 shows an intraoral photograph of the mass and normal surrounding tissues. The patient did not show any medical history.

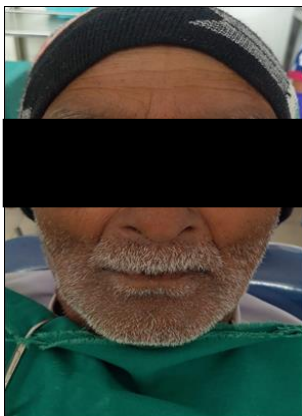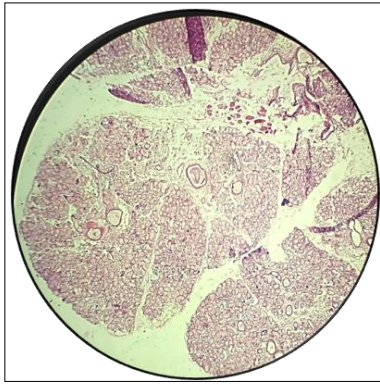


Fig 1

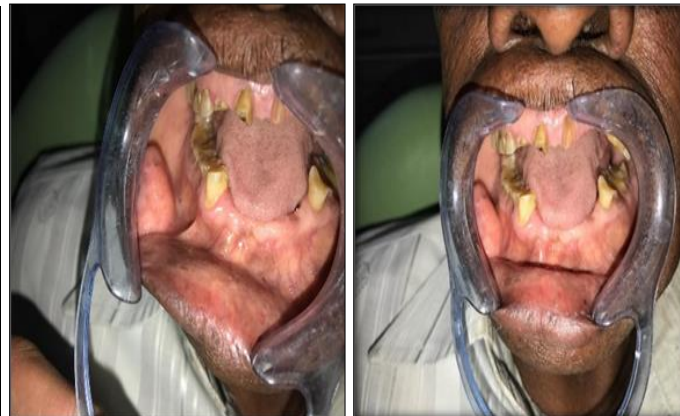

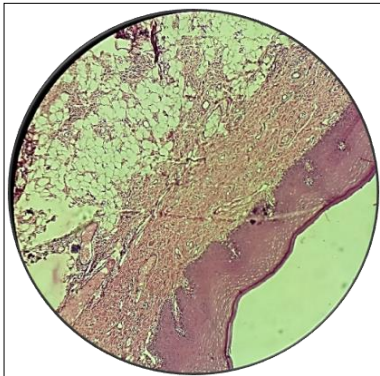
Fig 2

Histopathological findings



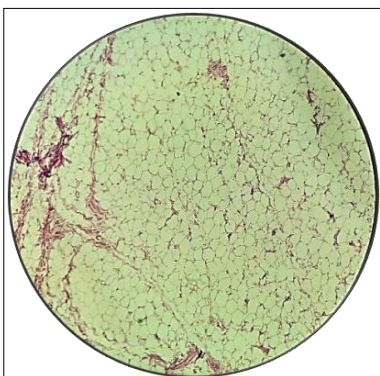
4x

The lesional tissue is separated from overlying parakeratinized stratified squamous epithelium by connective tissue which is composed of collagen fibres fibroblasts and blood vessels, change written matter, see next description



10x

The lesional tissue is separated from overlying parakeratinized stratified squamous epithelium by connective tissue which is composed of collagen fibres fibroblasts and blood vessels



40x

Hematoxylin and eosin stained section shows lesional tissue composed of closely packed mature adipocytes with clear cytoplasm and flat nucleus seen admixed with collagen fibres.

Fig 3

Histopathological analysis

In histopathological examination In lipomas, fibro-connective tissue and blood vessels could be seen between the adult adipocytes, and fibres surrounds these structures. The adipocyte has cytoplasm and nuclei near the border and a phospholipid vesicle in the centre. They are well-defined in the perivascular tissues, which is due to an encircling fibre sac. [fig 3] No abnormalities or recurrence was noted on 1-year follow-up and the patient did not complain of recurrence.

Discussion

The "hypertrophy theory," which claims that obesity and unintentional growth are postulated to be the pathogenic reasons for intraoral lipoma. Development of these oral lesions may be influenced by the presence of adipose tissue. When it comes to describing lesions that appear in regions devoid of previous adipose tissue, this explanation is less persuasive [10]. Diagnosis is made between the age of 60 and 80 [11]. Although surgical treatment is the best considered option for lipomas nowadays Steroid injections are a typical medical treatment for lipomas that cause local fat to atrophy and reduce the size of the tumour. They work best on lipomas with a diameter of less than an inch. A 1:1 mixture of lidocaine and triamcinolone acetonide injected into the centre of the tumour on a monthly basis may help the lesion shrink [12].

Conclusion

The tumours known as lipomas of the oral cavity are uncommon tumours that can vary in appearance based on histology and clinical assessment. For patients with oral lipoma, conservative surgical excision is the preferred course of action for preventing recurrence and assuring a long-term favourable prognosis.

Acknowledgement

Author greatly acknowledges the support provided by both the departments of Oral Surgery and Oral Pathology for reaching the right diagnosis and carrying out the treatment smoothly & efficiently.

Conflict of Interests

Author hereby declares no conflict of interest.

Reference

1. JGAM de Visscher. "Lipomas and fibrolipomas of the oral cavity," Journal of Maxillofacial Surgery,1982;10(3):177– 181.
2. JC Hatziotis. "Lipoma of the oral cavity," Oral Surgery, Oral Medicine, Oral Pathology,1971;31(4):511–524.
3. De Sanctis CM, Zara F, Sfasciotti GL. An Unusual Intraoral Lipoma: A Case Report and Literature Review. Am J Case Rep,2020;21:e923503. doi: 10.12659/AJCR.923503. PMID: 32564054; PMCID: PMC7327751.
4. Egido Moreno S, Lozano Porras AB, Mishra S, Allegue Allegue M, Marí Roig A, López López J. Intraoral lipomas: Review of literature and report of two clinical cases. J Clin Exp Dent,2016;8:597-603. [Google Scholar]
5. Mehendiratta M, Jain K, Kumra M, Manjunatha BS. Lipoma of mandibular buccal vestibule: a case with histopathological literature review. BMJ Case Rep,

- 2016, bcr2016215586. [PMC free article] [PubMed] [Google Scholar]
6. Manor E, Sion Vardy N, Joshua BZ, Bodner L. Oral lipoma: analysis of 58 new cases and review of the literature. *Ann Diagn Pathol*,2011;15:257-261. [PubMed] [Google Scholar]
 7. Furlong MA, Fanburg Smith JC, Childers EL. Lipoma of the oral and maxillofacial region: Site and subclassification of 125 cases. *Oral Surg Oral Med Oral Pathol Oral Radiol Endod*,2004;98:441-450. [PubMed] [Google Scholar]
 8. Kapakuya A, Subasi M, Dabak N, Ozkul E. Osseous lipoma: eleven new cases and review of the literature. *Acta Orthop Belg*,2006;72:603-614. [PubMed] [Google Scholar]
 9. Cocca S, Viviano M, Parrini S. Unusual complications caused by lipoma of the tongue. *J Kor Assoc Oral Maxillofac Surg*,2017;43:S6-S8. [PMC free article] [PubMed] [Google Scholar]
 10. TKD Gupta. "Tumors and tumor-like conditions of the adipose tissue," in *Current Problems in Surgery*, M. M. Ravitch, Ed., Year Book Medical, Chicago, Ill, USA, 1970, 1-60.
 11. Mehendrrata M, Jain K Kumra, M Manjunath BS. Lipoma of mandibular buccal vestibule: a case with histopathological literature review. *BMJ Case Rep*, 2016.
 12. Intraoral Lipoma. A Case Report L. K. Surej Kumar, Nikhil Mathew Kurien, Varun B. Raghavan, P. Varun Menon, and Sherin A. Khalam. *Case Reports in Medicine*, 2014. Article ID 480130.